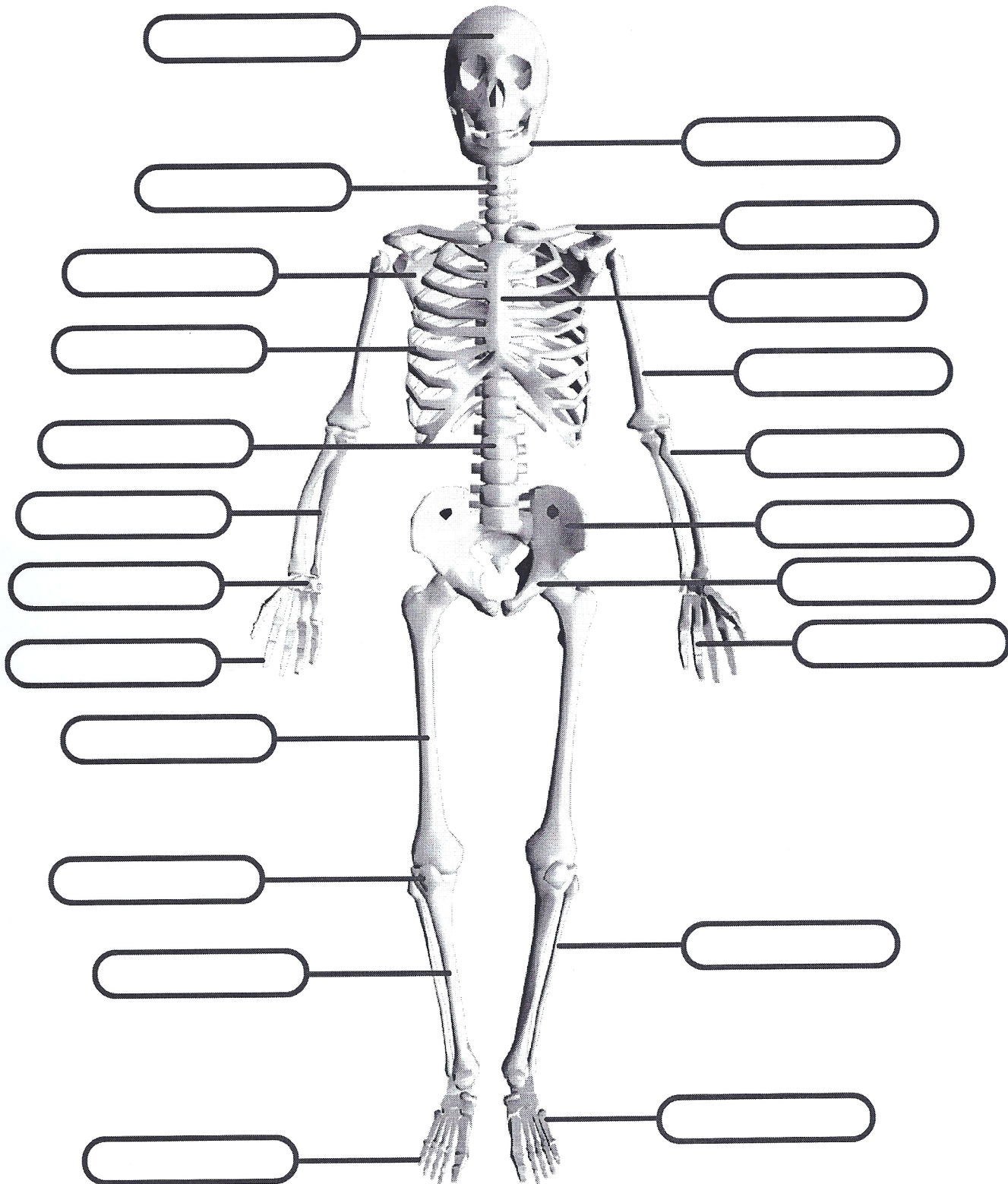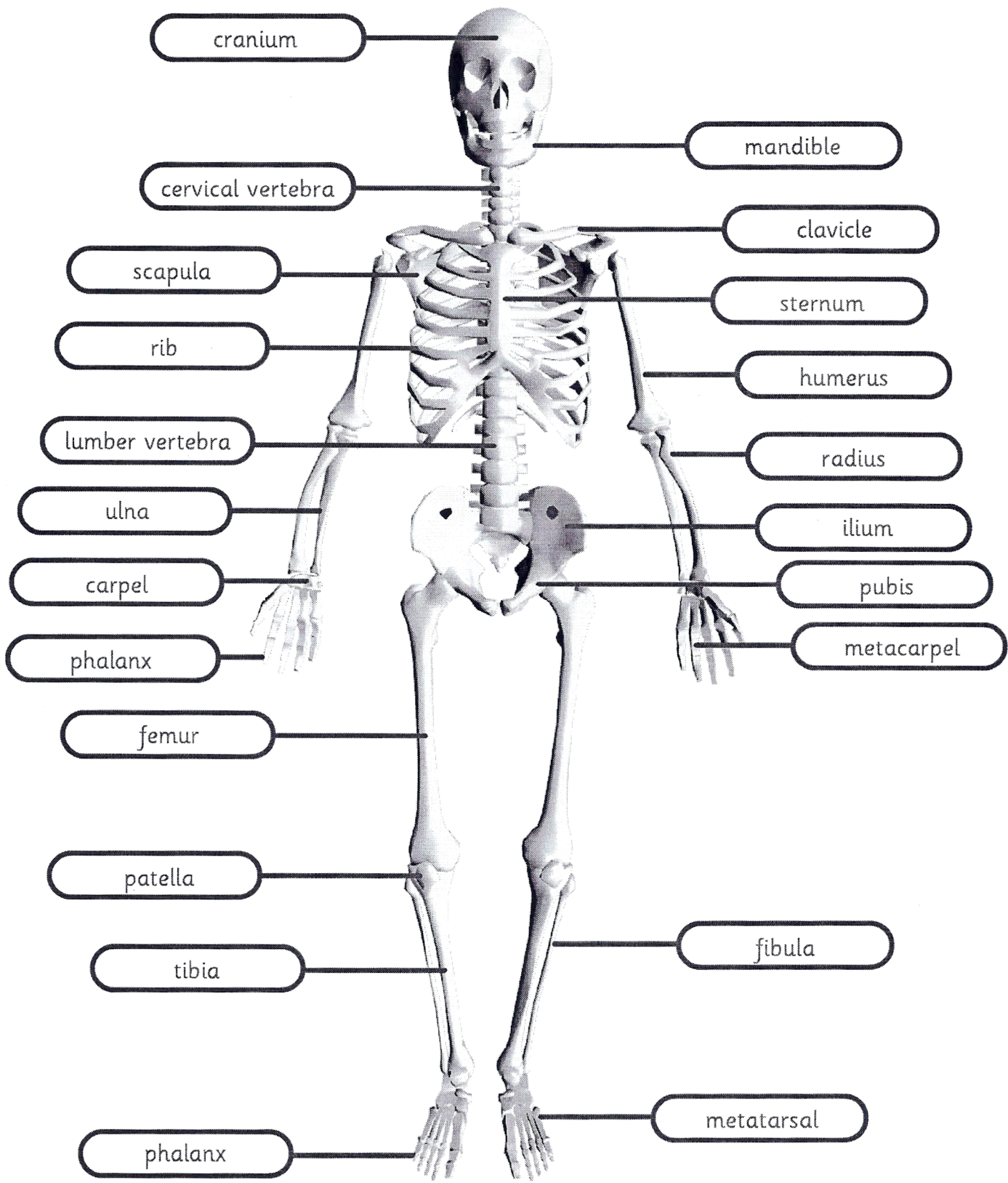


cranium mandible cervical vertebra lumbar vertebra phalanx carpel metatarsal
 metacarpel ilium ulna rib femur tibia radius fibula sternum clavicle scapula patella
 pubis humerus



cranium mandible cervical vertebra lumber vertebra phalanx carpel metatarsal
 metacarpel ilium ulna rib femur tibia radius fibula sternum clavicle scapula patella
 pubis humerus